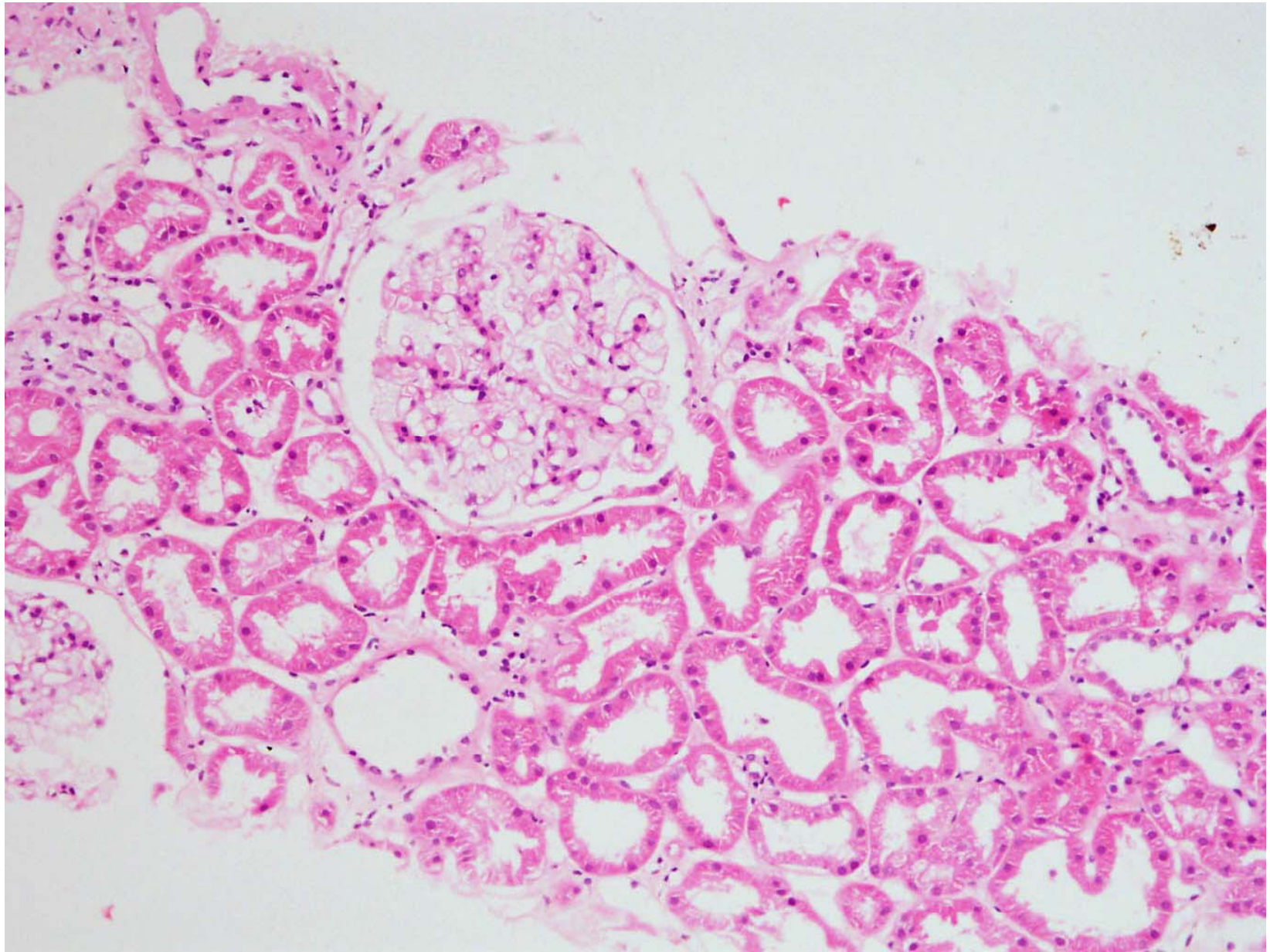
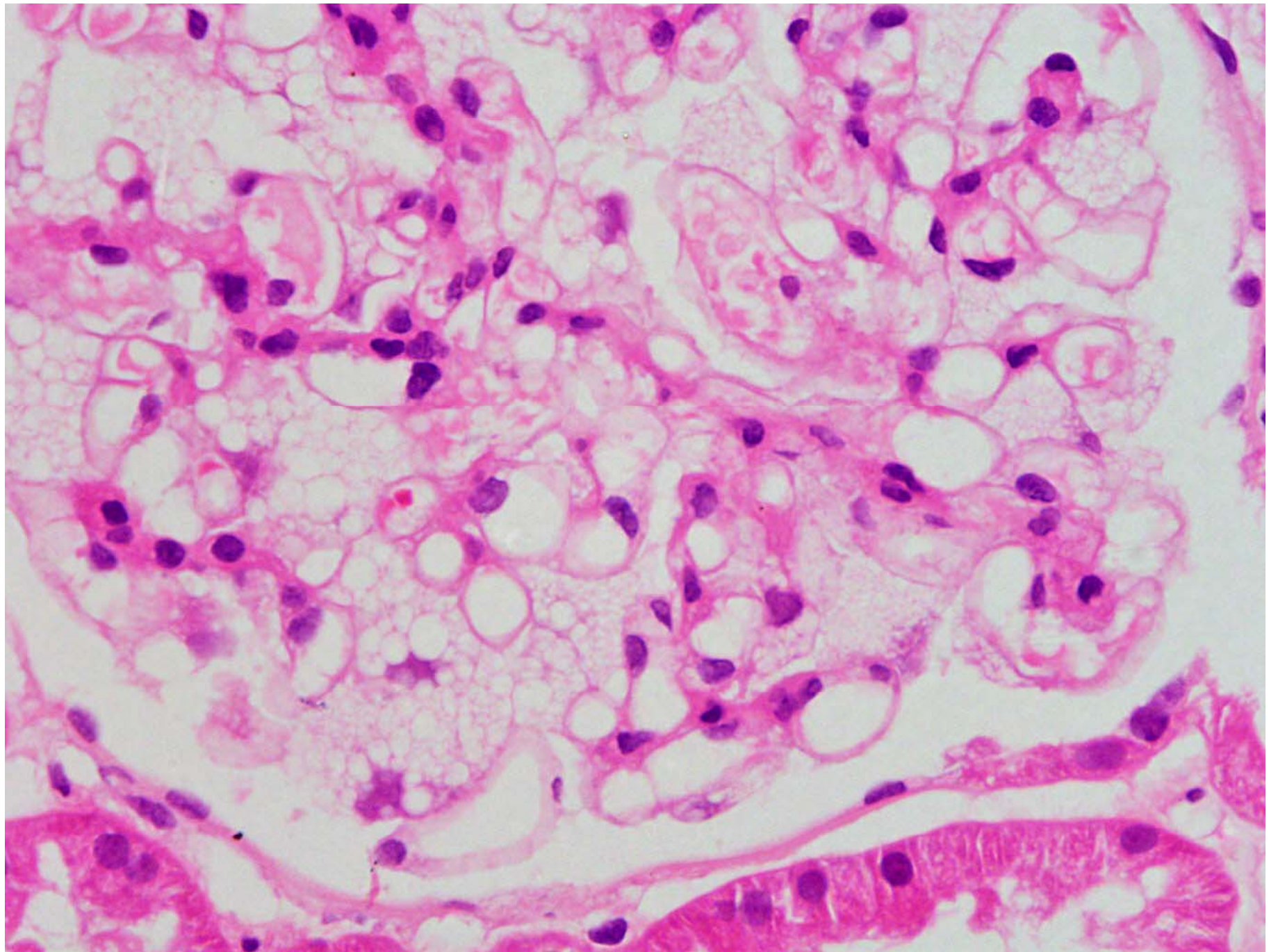


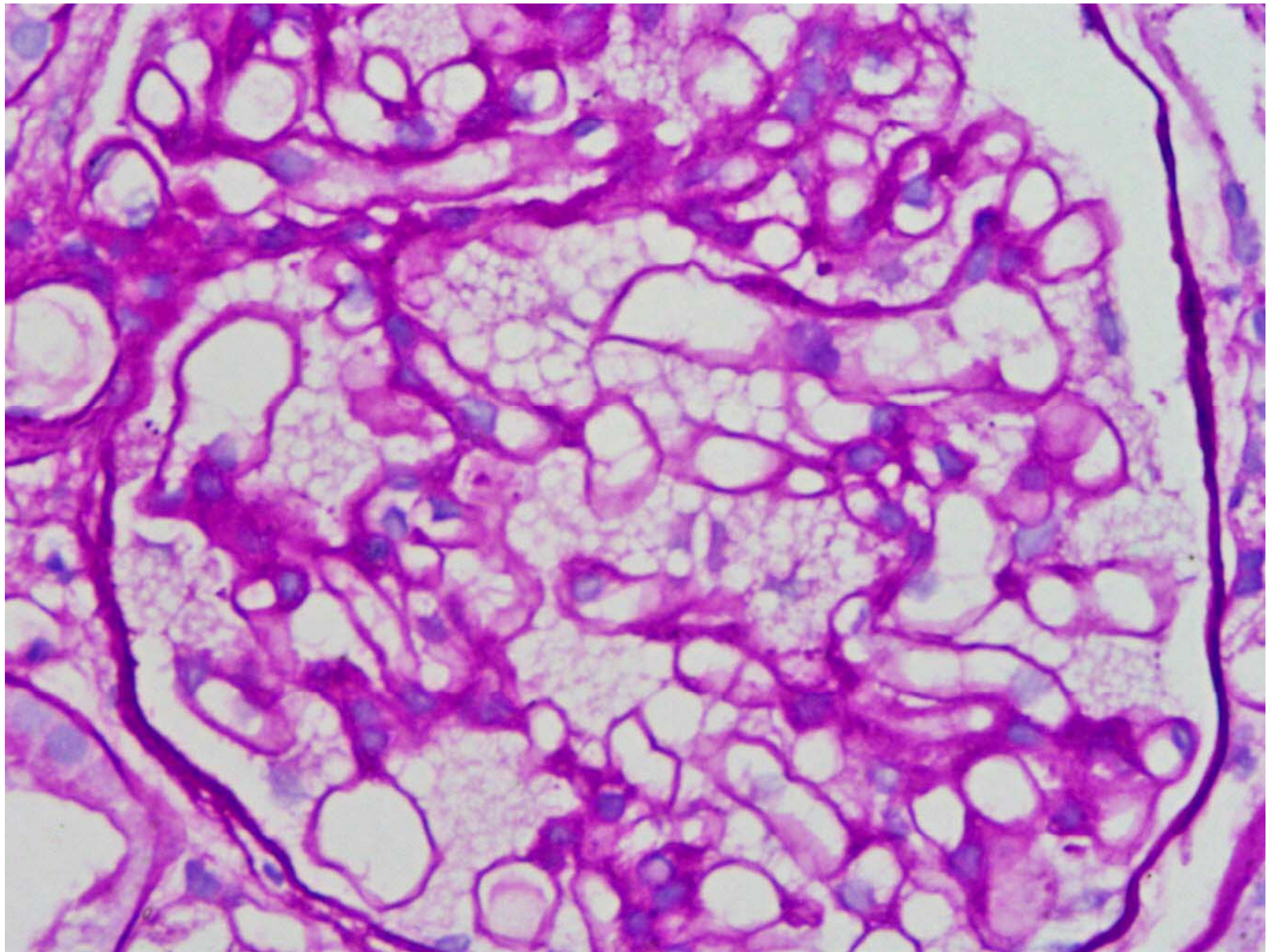
# Quiz Case

Dr Amit Dinda and team  
AIIMS, New Delhi

- Case History
- 29 Year old male with swelling both legs since two months.
- On investigations
- Urine Protein (spot) ++, Microscopy: NAD
- 24 hours urinary protein excretion 1.6gm
- Urea: 24 mg%
- Creatinine: 1.1 mg%
- Viral markers: Negative
- ANA, ANCA: Negative
- C3 :105 mg%
- USG: Normal Kidney size and echotexture
- Kidney biopsy performed







What's your possibilities?

Please mail possibilities at editors  
email address